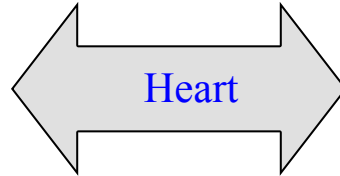


Exam on right side

Normal

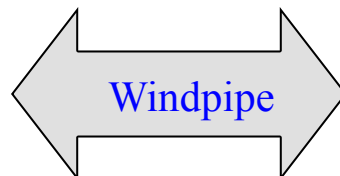Problem

- Fainter than left side, but same rate and rhythm
- Listen under the elbow



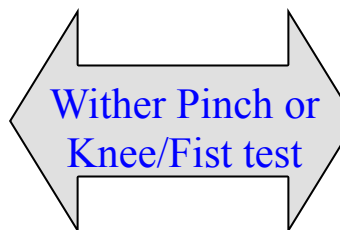
- Confirm abnormal findings by listening to left again

- Dry, air rushing sounds



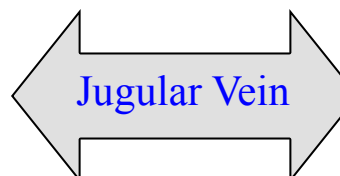
- Noisy air flow
- Grunts

- Drops away from pinch
- No grunting



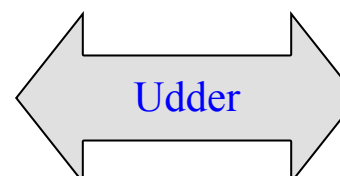
- Stiffens up
- Holds breath
- Grunts

- Should not show
- No pulse



- Distended
- Wave with pulse

- Soft, even size of quarters
- CMT– All 4 are similar
- Teats have normal skin
- No teat end damage



- Firm, painful enlarged quarter
- CMT– Thickened, darker
- Teats: scabs, thickened, swollen, poor ends